Het bevolkingsonderzoek, geschiedenis en de chirurgie

Prof. dr. Theo Wobbes

Emeritus Hoogleraar Chirurgische oncologie
UMC St Radboud

H.I.P.-studie

Health Insurance Plan, New York

- start in 1963
- gerandomiseerd, 40-64 jaar
- ook lichamelijk onderzoek
- 31.000 patiënten deden mee
- attendance rate 65%
- 50% van de tumoren < 2 cm
- sterftereductie na 10 jaar 30%

Malmö-studie

- start in 1977
- gerandomiseerd, 45-69 jaar
- alleen mammografie
- 59% niet-invasief en/of < 1 cm
- 82% negatieve oksellymfeklieren
- gemiddelde tumorgrootte in controlegroep 2 cm
- 53% negatieve oksellymfeklieren
- indien ≥ 55 jaar 20% sterftereductie (1988)

D.O.M.-studie

Diagnostisch onderzoek mammacarcinoom Utrecht

- start in 1974
- niet gerandomiseerd, 50-64 jaar
- xero-mammografie en lichamelijk onderzoek
- 39% niet invasief en/of 1 cm
- 66% negatieve oksellymfklieren
- uiteindelijk 46% sterftereductie

Xeroradiography (1970)

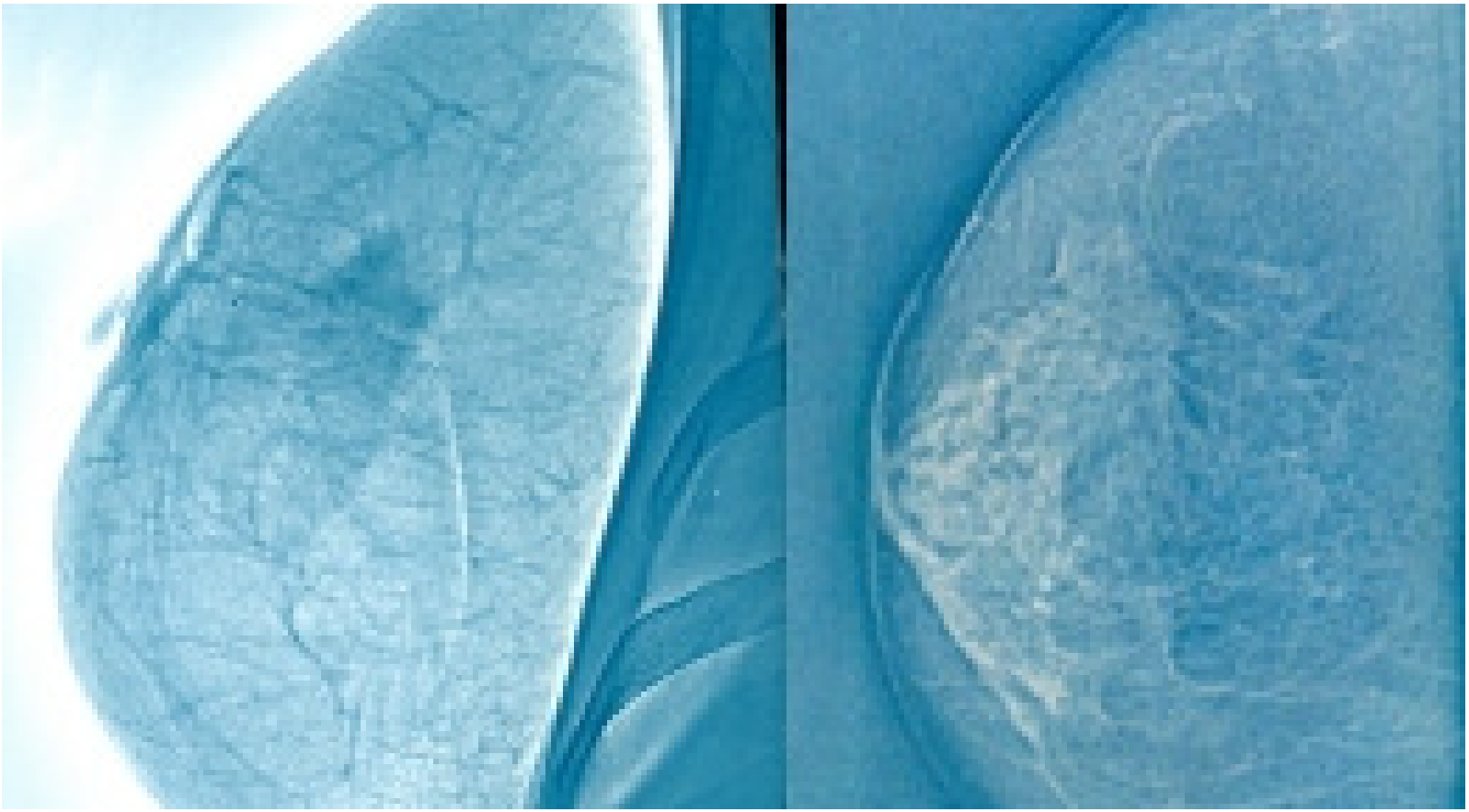

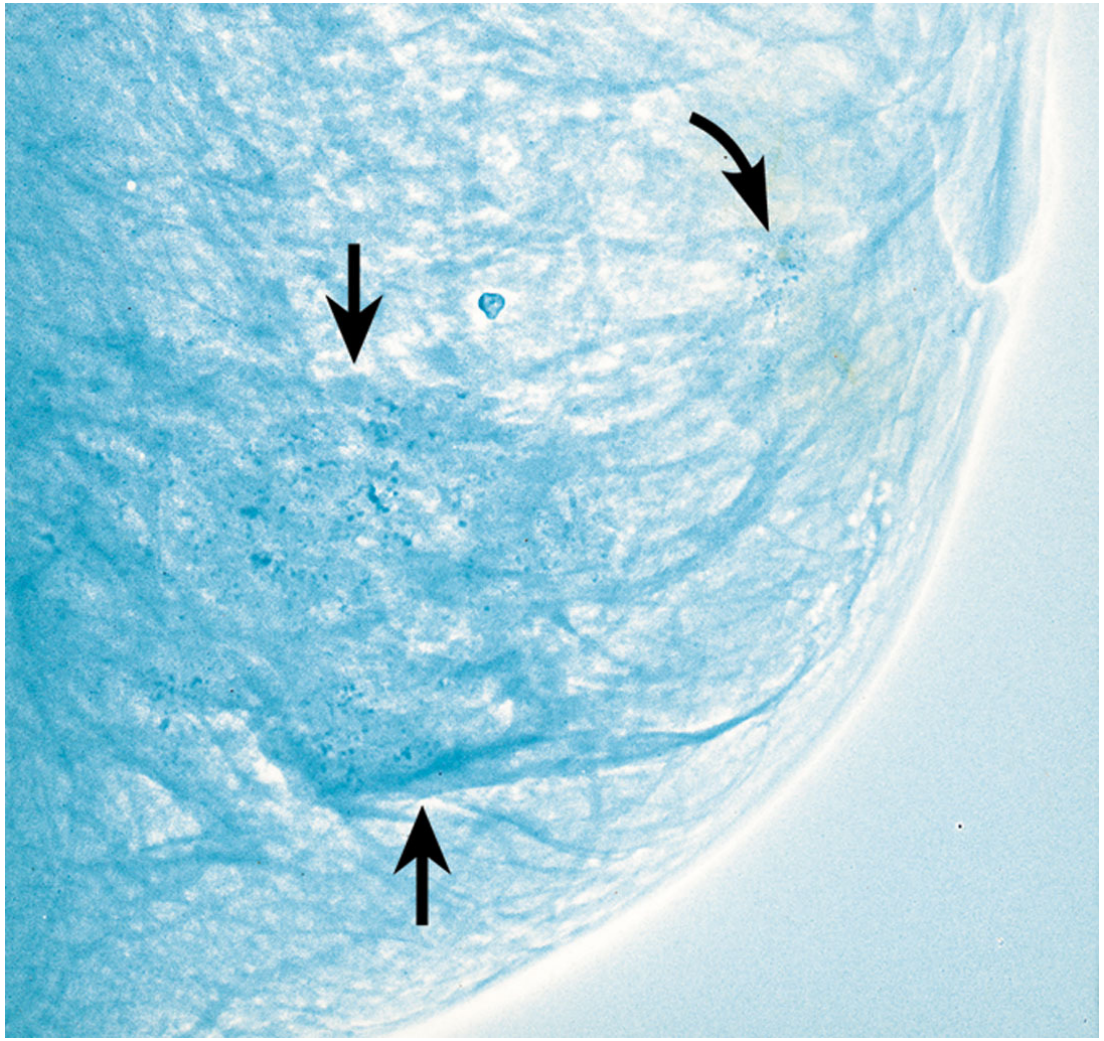

Nijmeegse studie

- start in 1975
- case control-studie, 35-65 jaar
- in 1982 vier screeningsrondes
- in eerste ronde detectie 5,2 per 1000
- in tweede ronde 2,8 per 1000
- in derde ronde 2,4 per 1000
- in eerste ronde 22% niet invasief of < 1 cm

Bron: J.H.C.L. Hendriks, proefschrift 1982.

Chirurg en borstkankerscreening

Wat was nieuw in die tijd?

Niet palpabele mammalaesie

- kleine carcinomen
- in situ carcinomen
- microcalcificaties
- suspecte laesie

Chirurg en borstkankerscreening

Hoe krijgen we een diagnose?

Wat kan de mammografietechniek voor ons betekenen voor het begrip van mammacarcinoom?

Microcalcificaties

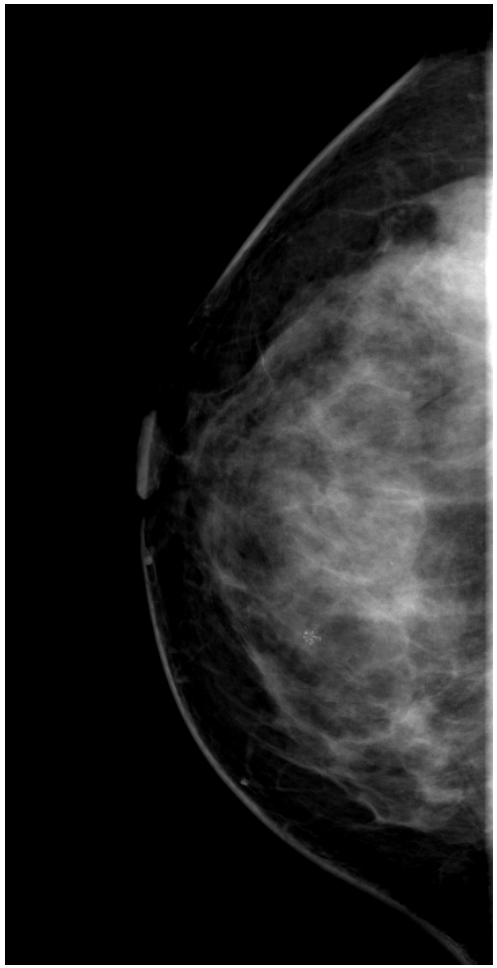

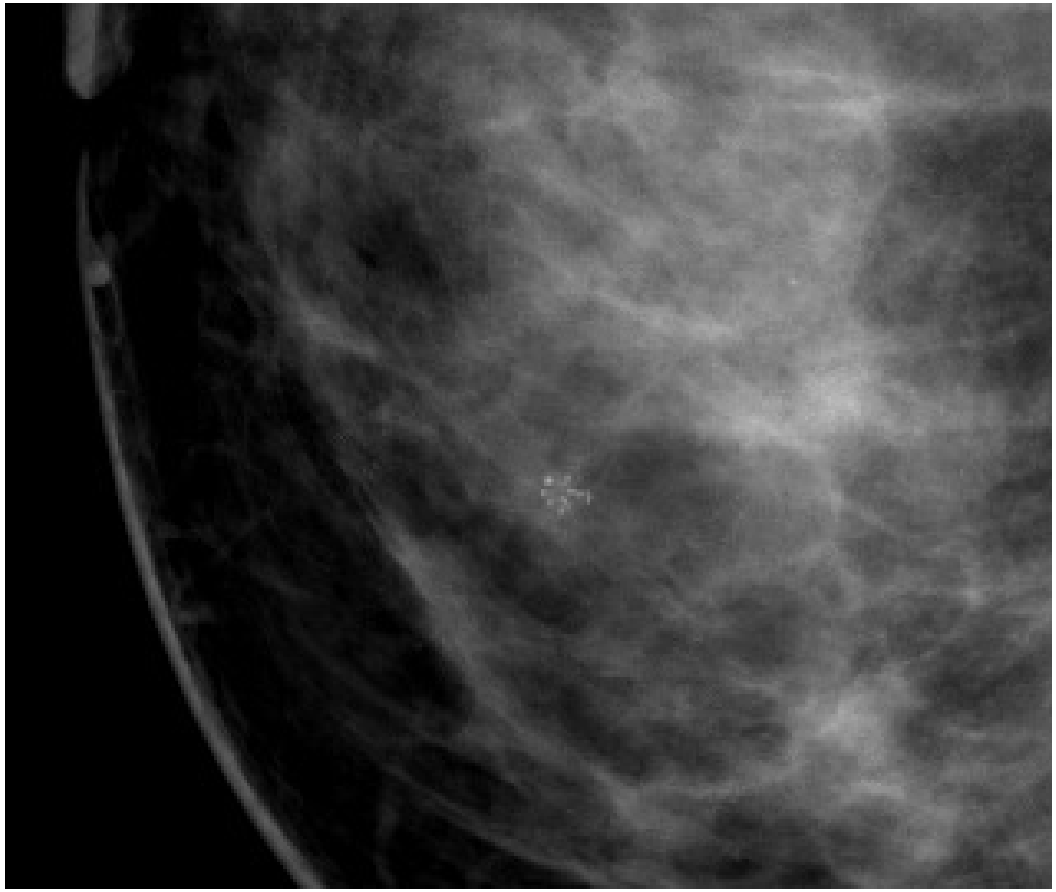

Microcalcificaties

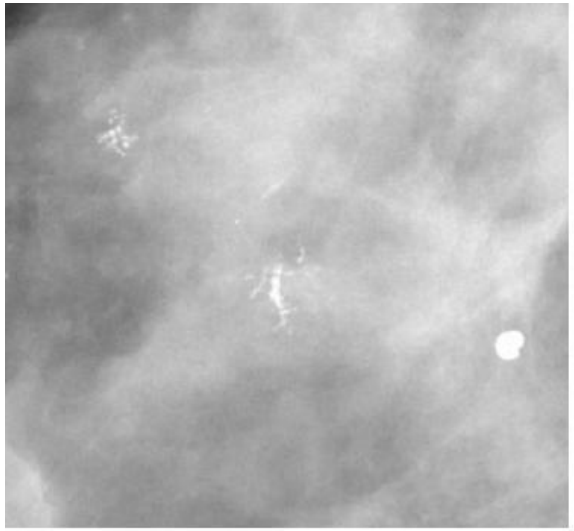

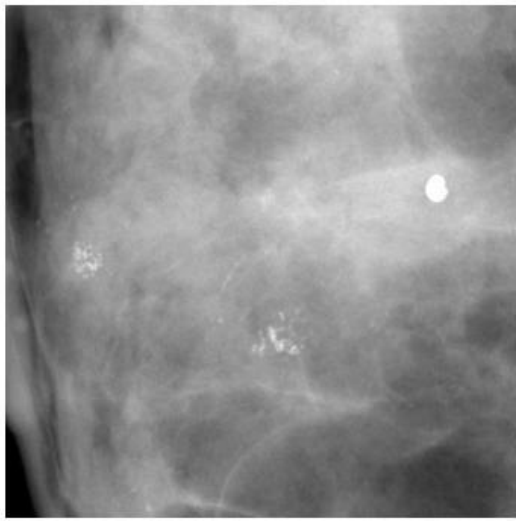

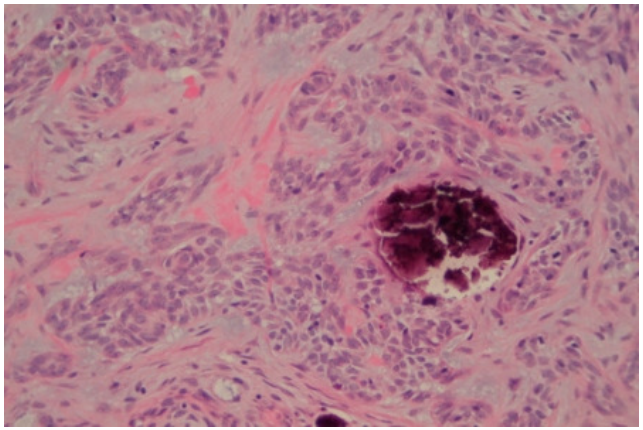



Invasief carcinoom met microcalcificaties

Problemen

However, the surgeon must sometimes be governed solely by the report of the radiologist. On the basis of competent mammographic interpretation, patients without clinical evidence of disease face at least a 25% chance of having cancer. The area of concern must be carefully localized preoperatively and the specimen radiographed, particularly if it contains calcifications. This requires a clear understanding of the problem and complete cooperation between the surgeon, the radiologist, and the pathologist.

Reports from screening programs for breast cancer detection vary widely in their detection rates, depending on the criteria used for selection of patients [1–6]. In the 27 Breast Cancer Detection Demonstration Projects in the United States sponsored by the National Cancer Institute and the American Cancer Society, 6 cancers per 1000 women examined have been detected, based on a preliminary report of the

the clinical findings? Are there mammographic findings without clinical corroboration? Are the mammograms adequate? The screening physicians have only to state the problem. The surgeon, together with the consulting roentgenologist, must resolve it. Often equivocal findings are not confirmed or surgery is not considered necessary. The wisdom of a decision to wait and follow the patient may not be apparent for months or even years, inasmuch as a period of a year or more may elapse before an occult cancer becomes clinically obvious [7].

Clinical Examination

The physical findings and the mammographic interpretation must always be considered together in reaching a decision to biopsy. A significant mass or other definite clinical change with or without a posi-

RUTH E. SNYDER, M.D.

Department of Diagnostic Radiology, Memorial Sloan-K

Any decision to biopsy a breast on the basis of findings discovered in a screening program must carefully consider the expertise of the clinical examination, the technical quality of the mammograms, and the skill and experience of the radiologist reading them. A positive clinical examination with or without mammographic confirmation is indication for biopsy. However, the surgeon must sometimes be governed solely by the report of the radiologist. On the basis of competent mam-

Compressieplaat met gaatjes



Fig. 7.21 **Radiograph of breast and compression plate for localization**

Pre-operatieve röntgenlokalisatie

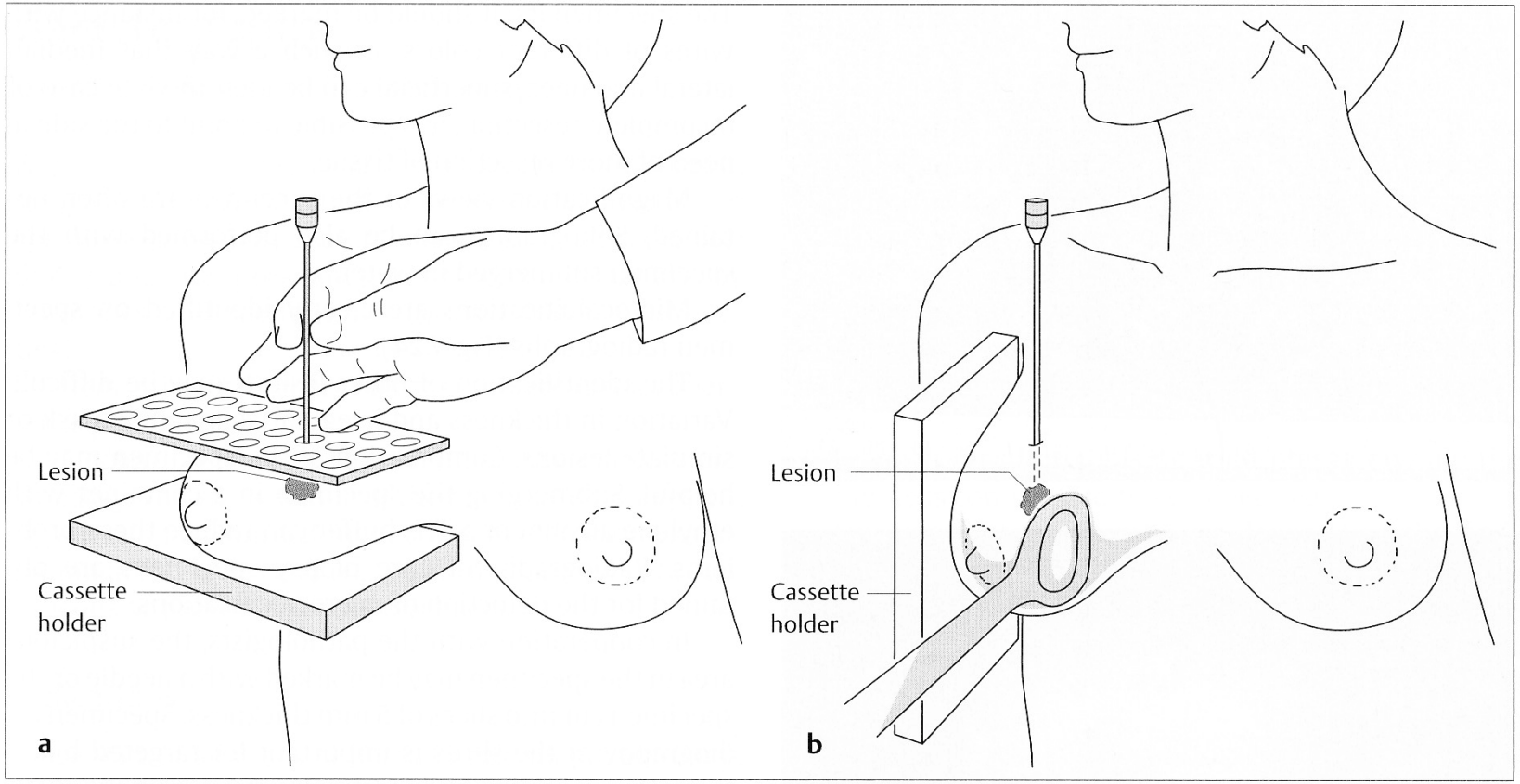

Fig. 7.22 a, b **Procedure of mammographic localization with fenestrated compression plate** (according to Kopans)
a Insertion of the needle parallel to the thoracic wall up to the lesion
b Lateral verification

Mammografie na lokalisatie suspecte laesie

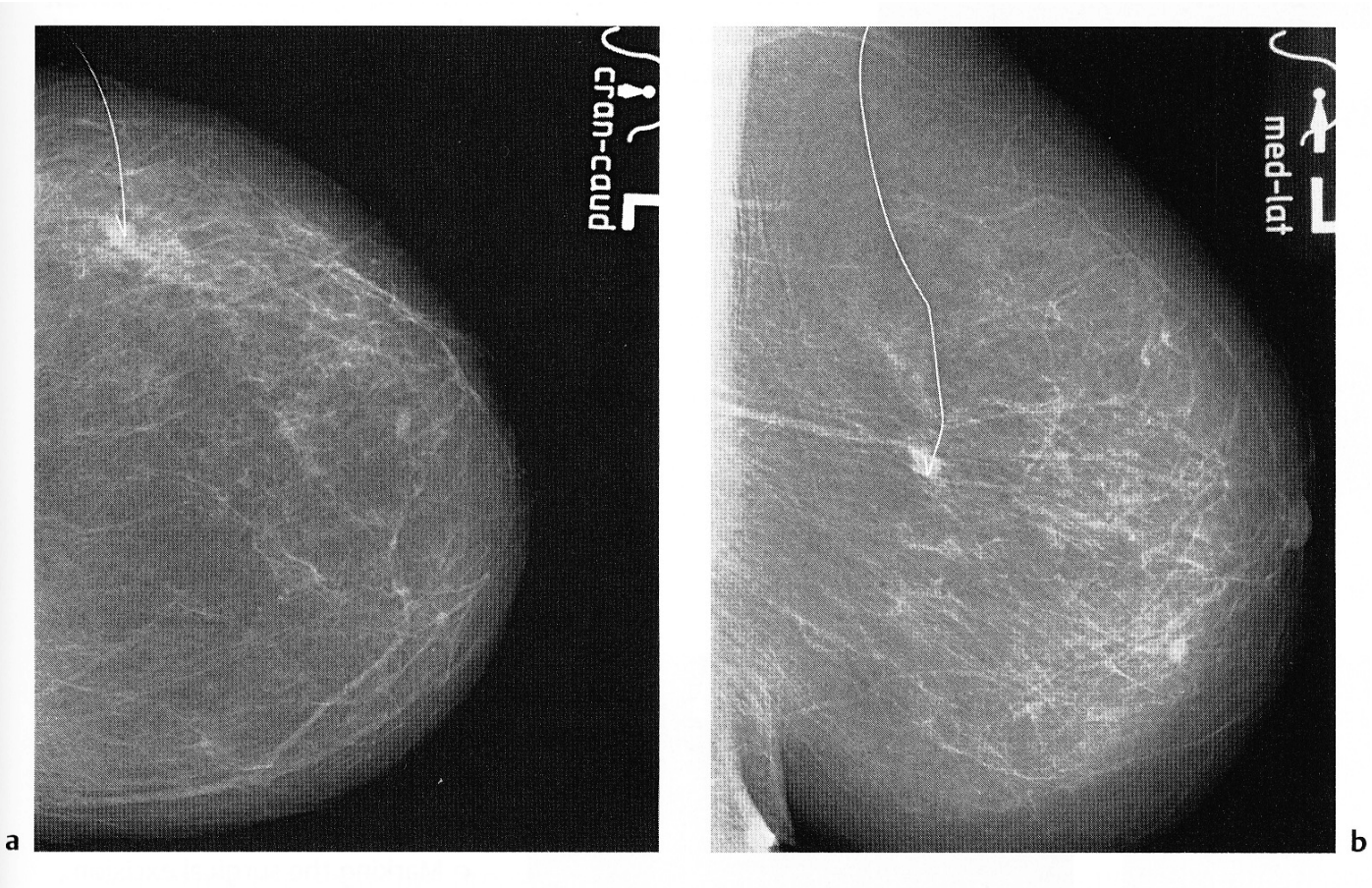

Specimenradiografie

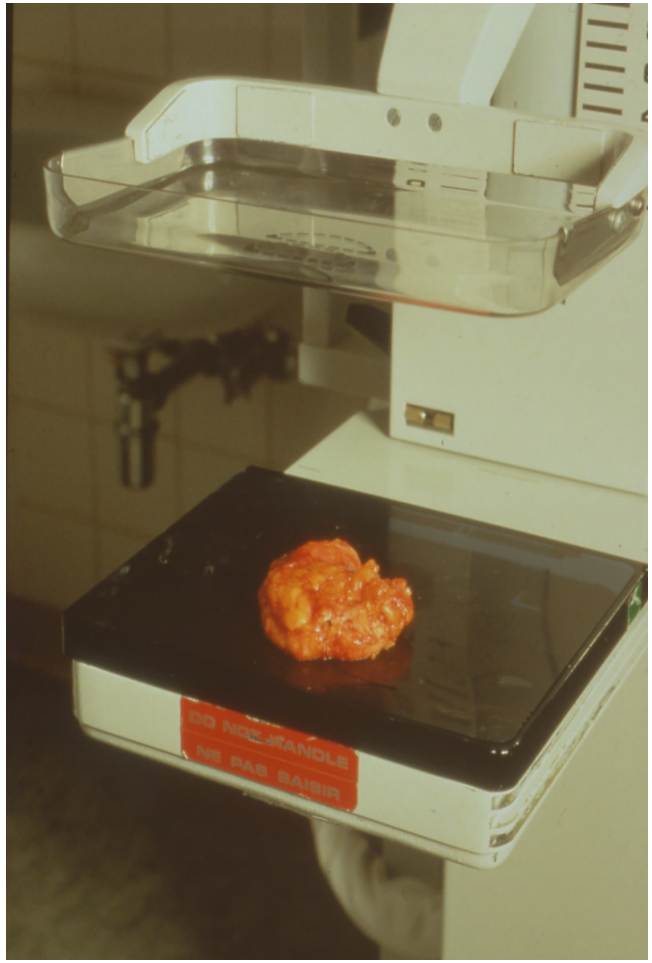

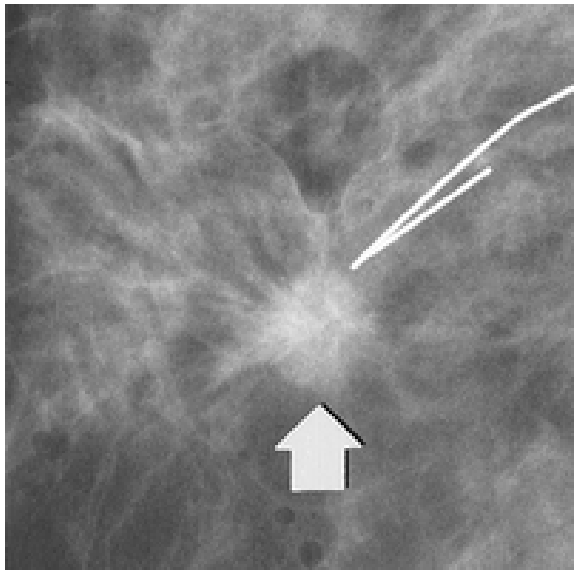

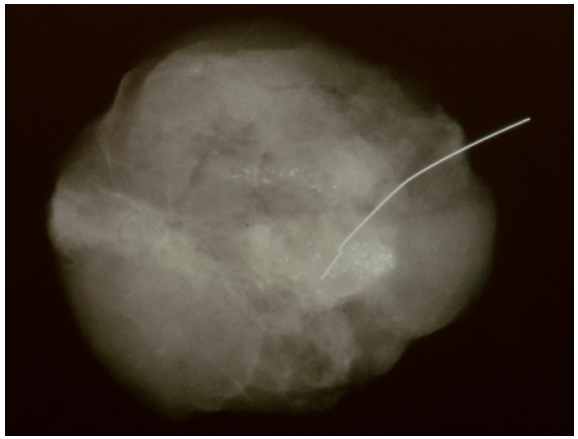

Inkten snijvlakken

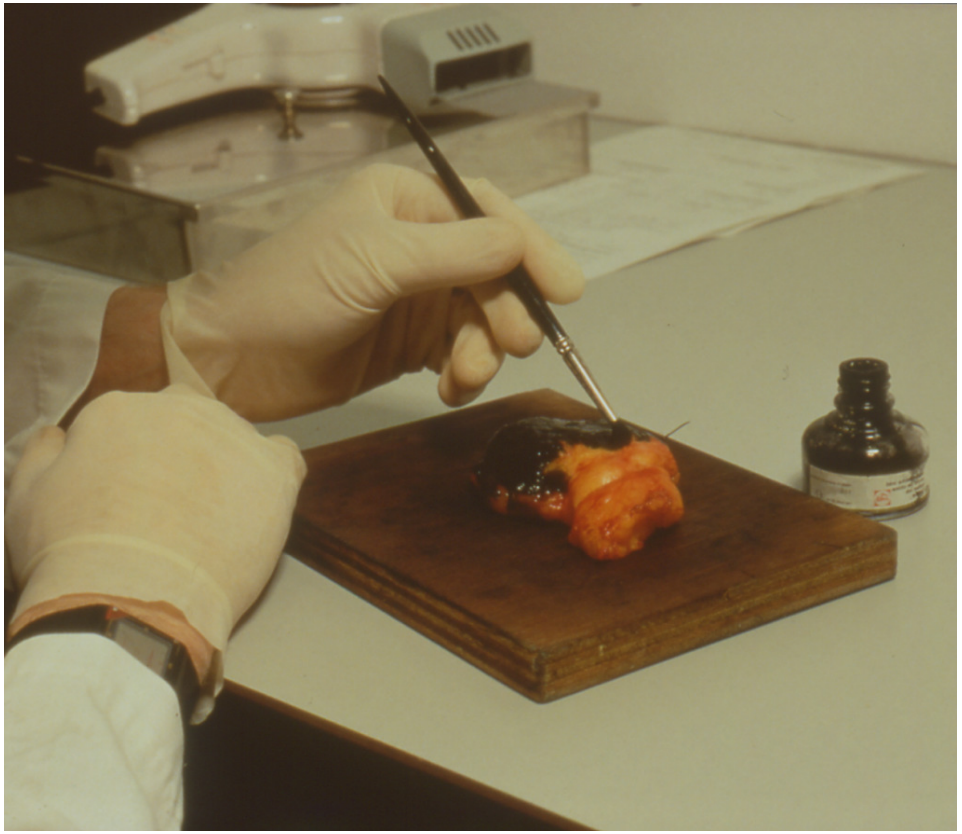

In plakjes snijden

Röntgenfoto maken van de plakjes

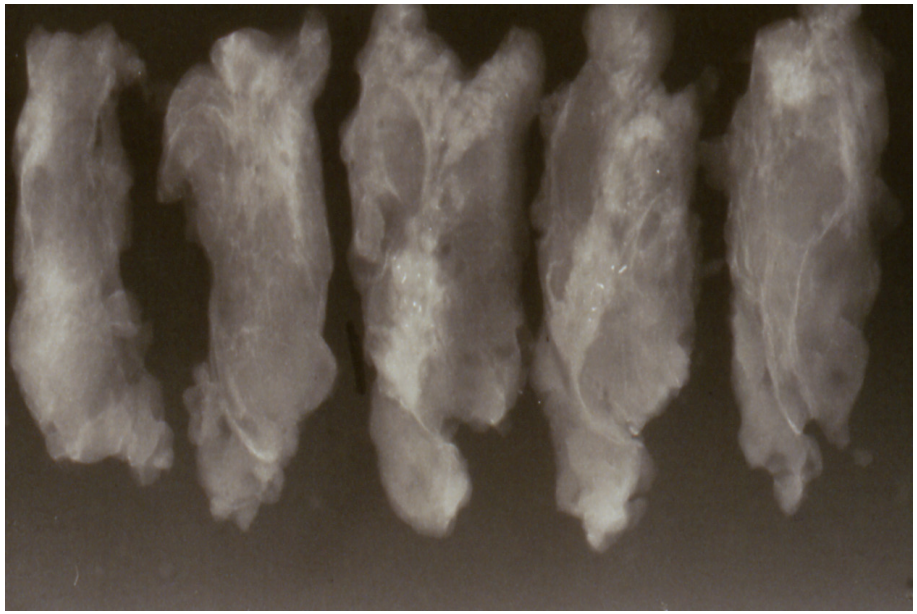

Ductaal carcinoom in situ

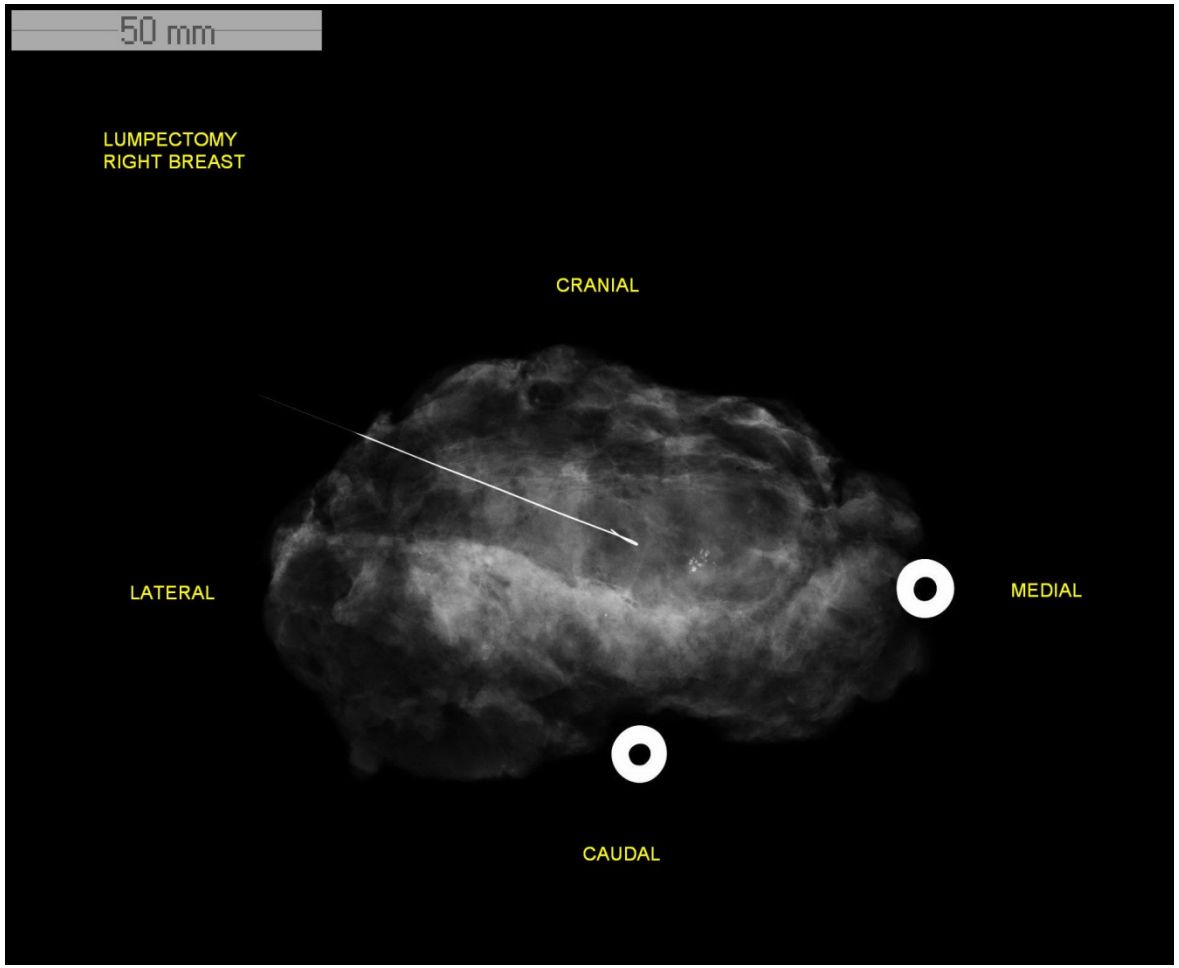

Specimenradiografie/lamellografie

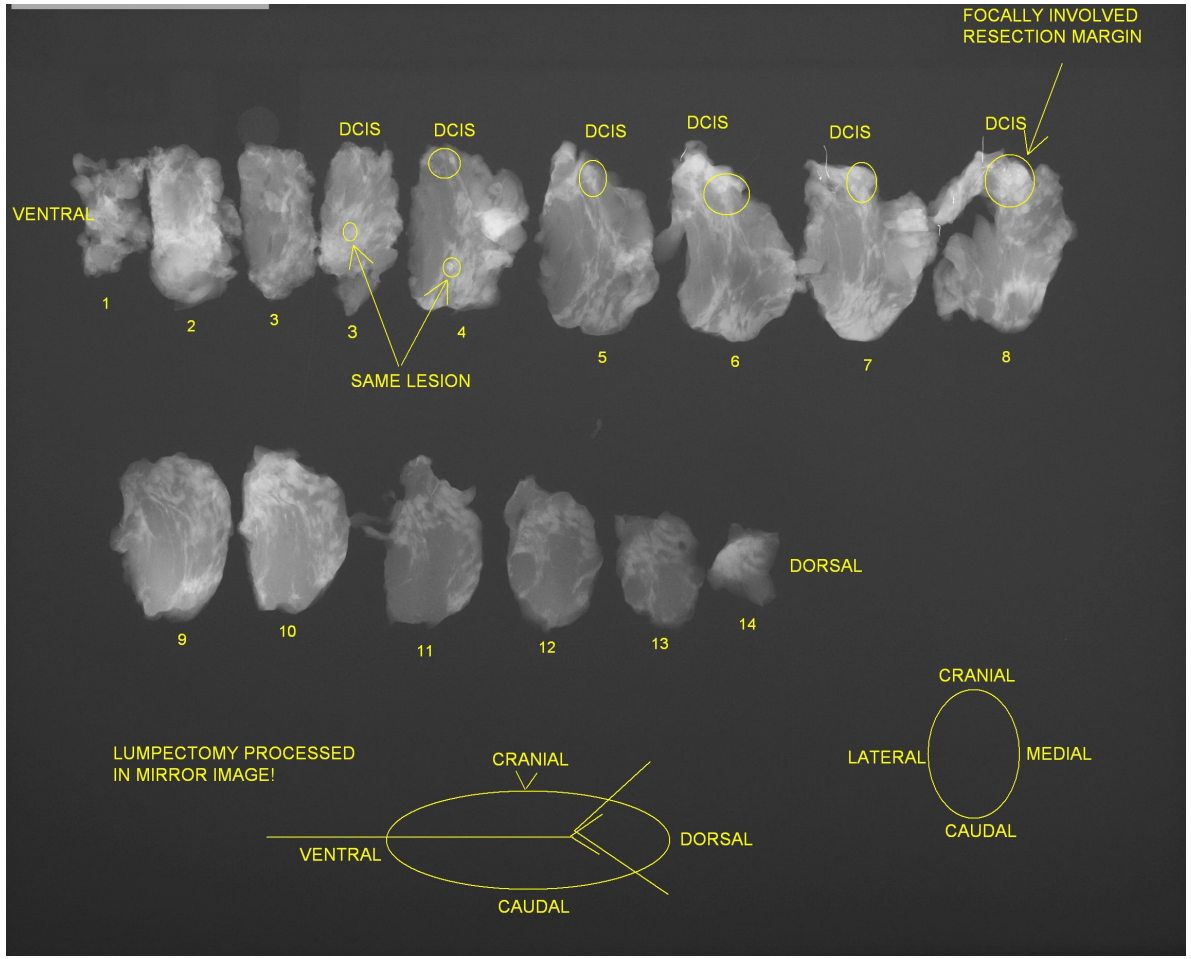

Mammografie

Als het mammacarcinoom dan zo goed kan worden vastgesteld met mammografie, wat kan er dan nog meer met de techniek?

Specimenopnames van plakjes mammaweefsel

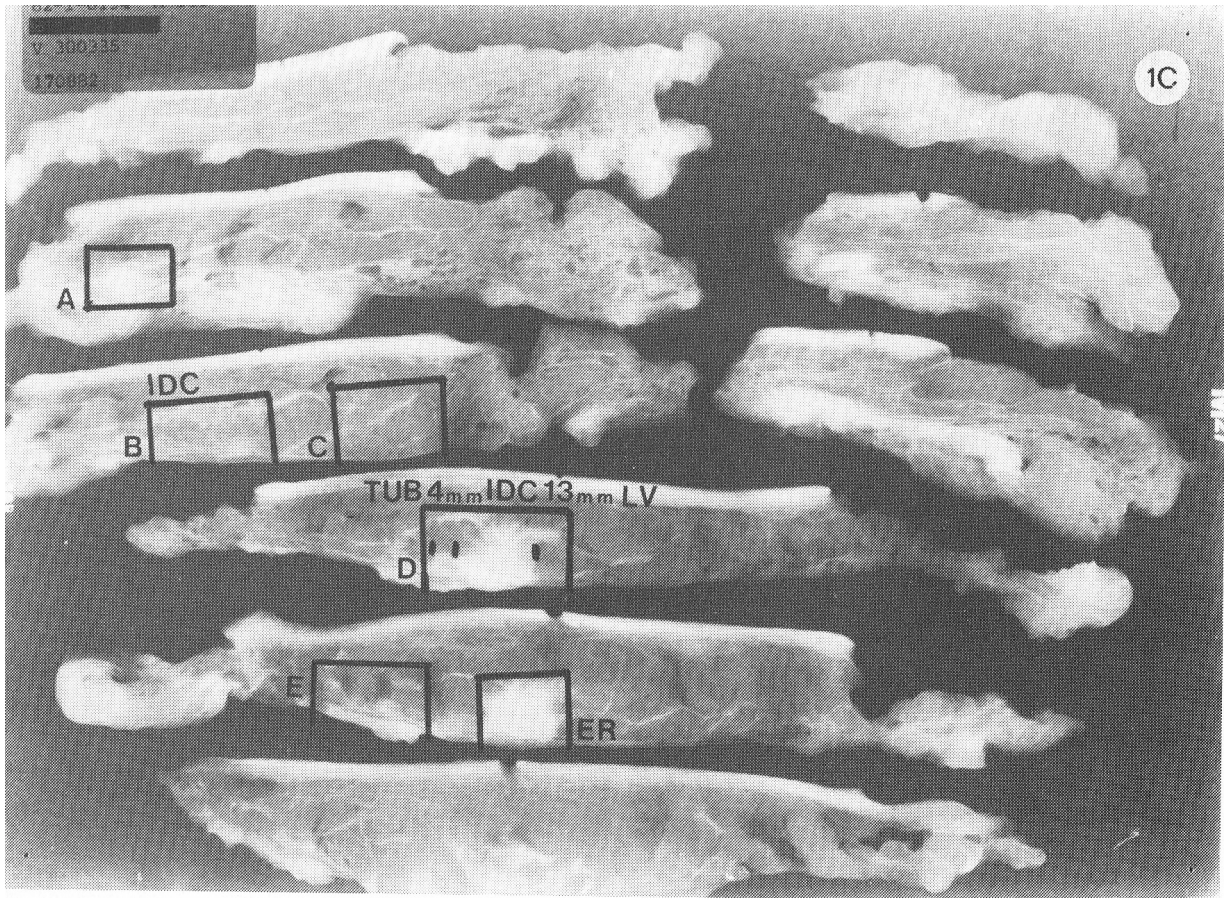

Holland R. et al. Cancer 1985; 56: 979-990.

In plakjes snijden van de borst

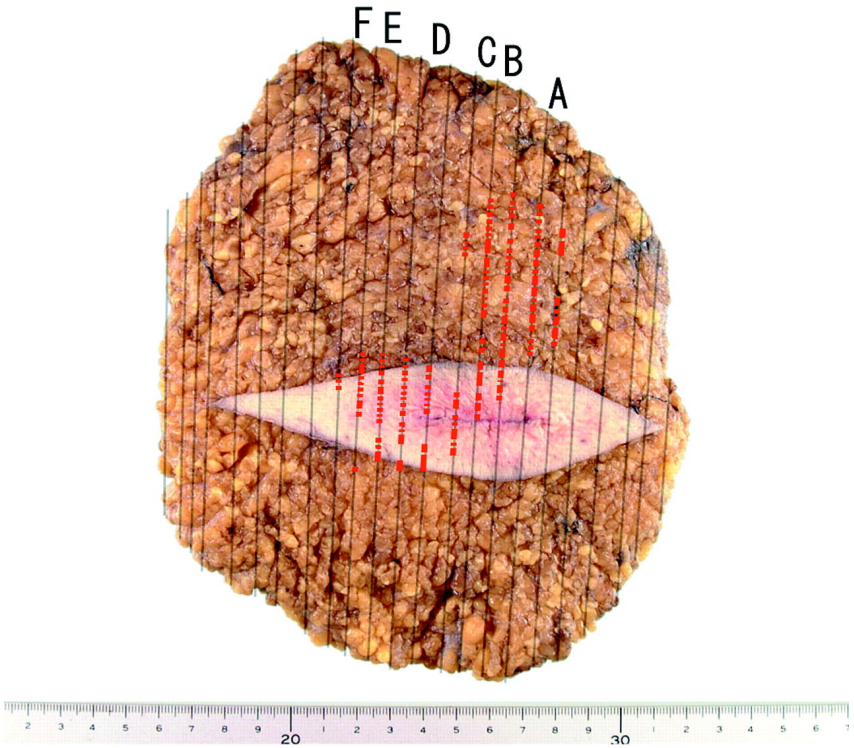

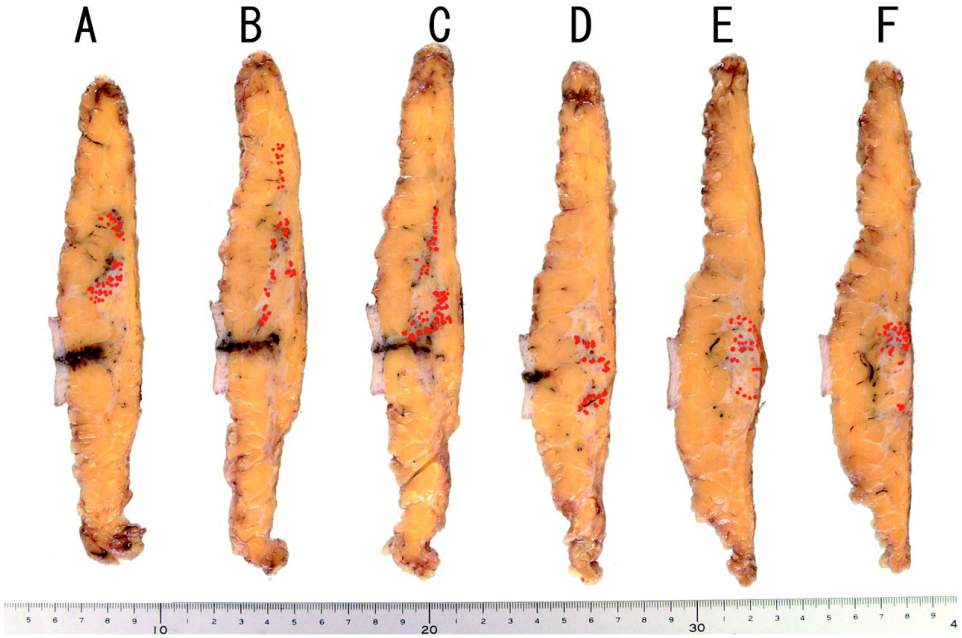

Amano G. et al. Jap J Clin Oncol 2005; 35: 149-153

Wat bleek?

- Nijmeegse patiëntenserie (282 met T_1 en T_2 tumoren)

- 37% geen tumor buiten biopsiegebied
- 20% tumor binnen afstand van 2 cm
- 43% tumor verder dan 2 cm
  - 27% verder dan 2 cm: non-invasief
  - 16 % ook invasief
  - Bij een marge van 3-4 cm nog bij 7-9% invasief en bij 4-9% niet-invasief carcinoom in de borst

Holland R. et al. Cancer 1985; 56: 979-990.

Monocentrisch/multicentrisch

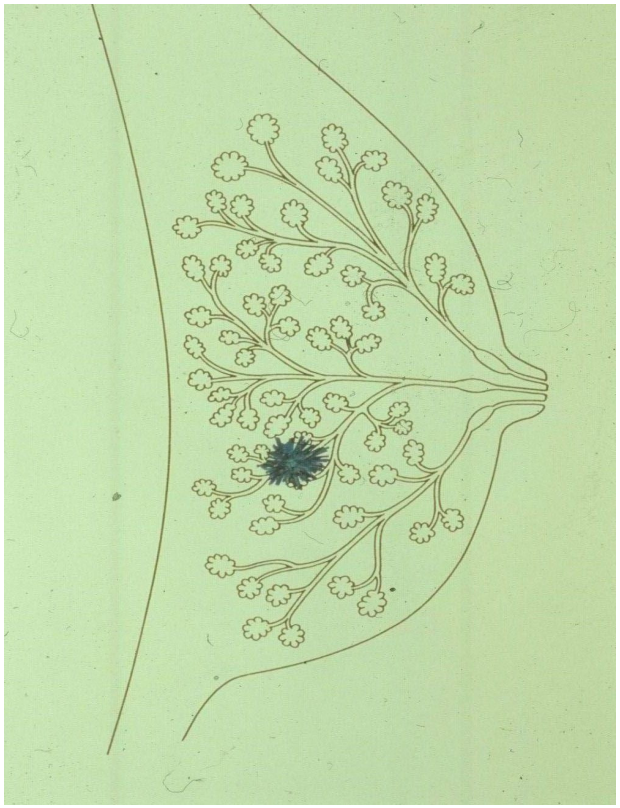

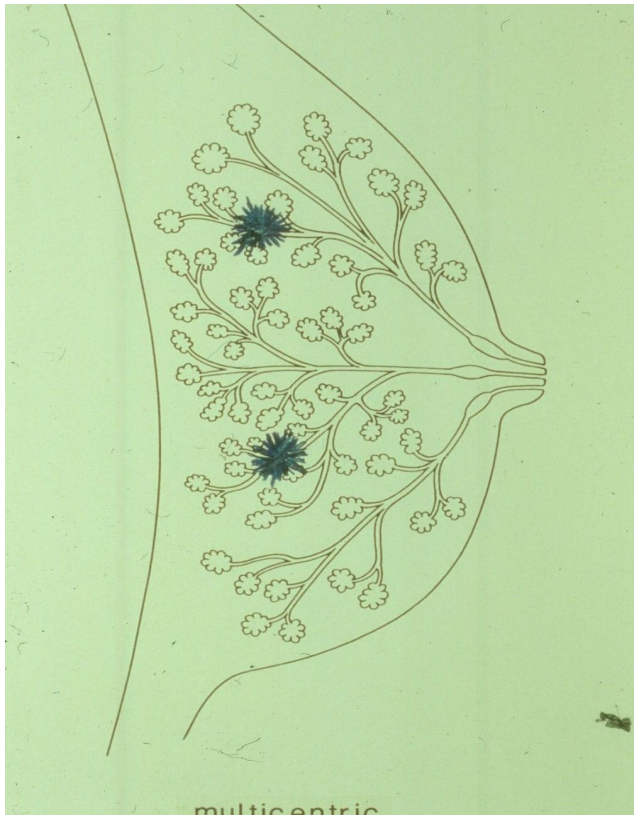

DCIS als deel van invasief carcinoom

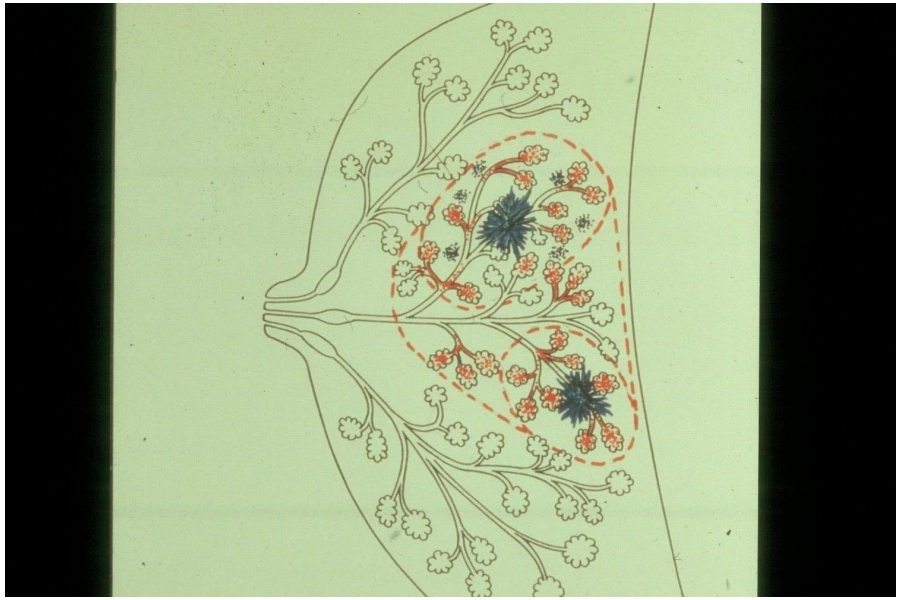

Specimenradiogram van mamma

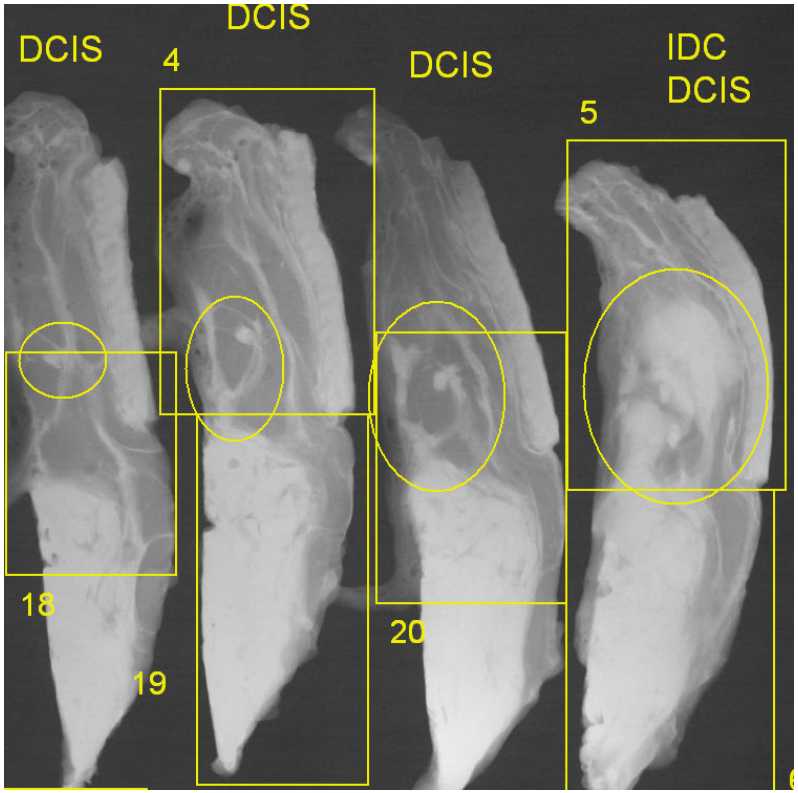

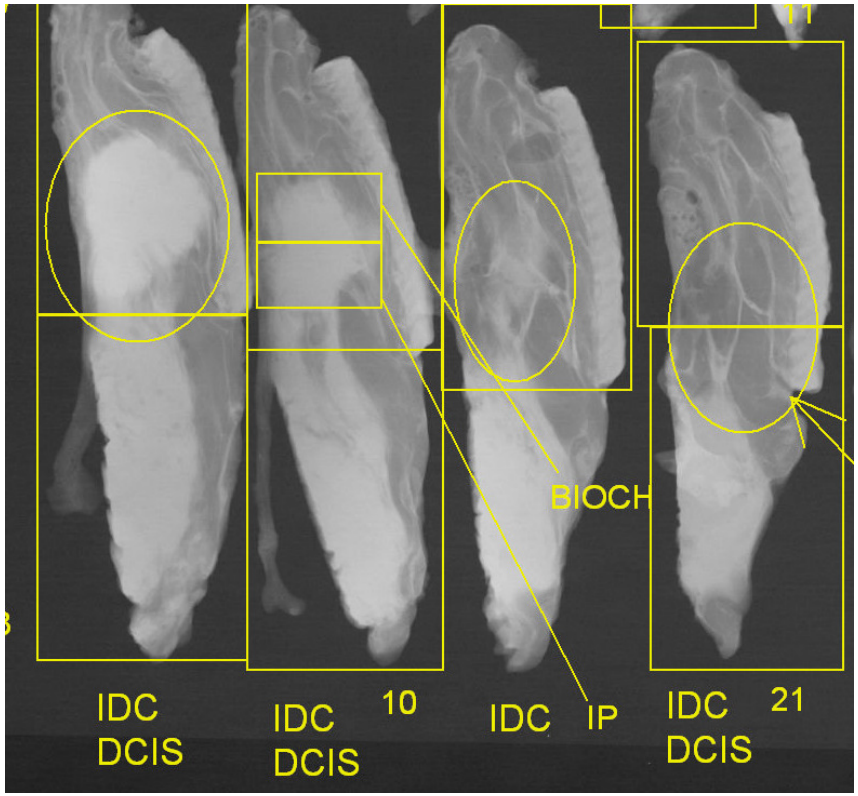

Ductaal carcinoom in situ

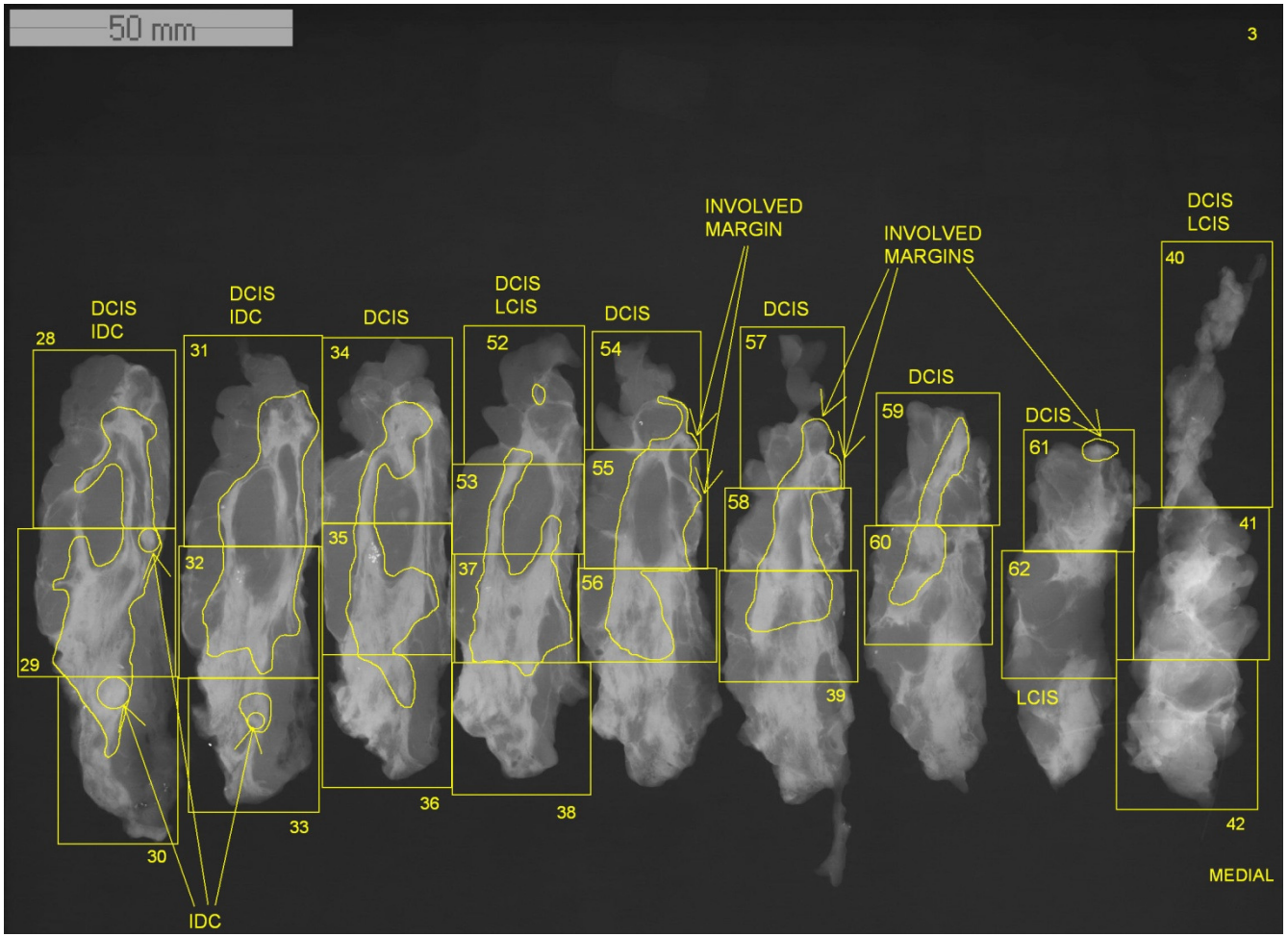

Wat heeft de screening ons geleerd?

- In de eerste plaats: sterftereductie
- Maar de radiologische technologie gaf de mogelijkheid de ware aard van mammacarcinoom op het spoor te komen: vaak multifocale ziekte (= twee of meer foci in hetzelfde kwadrant)
- Maar ook multicentrische ziekte (= twee of meer foci in andere kwadranten)

Multifocaliteit en multicentriciteit van mammacarcinoom

- Is een eigenschap die ertoe bijdraagt dat de borstsparende behandeling beperkingen heeft,
- Ook vaker okselkliermetastasen,
- Consequenties voor chirurg en radiotherapeut.