Erasmus MC
University Medical Center Rotterdam

Partial Breast Reconstruction

MBE Menke-Pluijmers, chirurg
Erasmus MC Rotterdam

Achtergrond

- Toepassing MST:
  - Overleving niet slechter
  - Behoud van body image en QoL
  - Psychische belasting lager

- Cosmetisch resultaat na MST afhankelijk van volume dat verwijderd wordt
  - Tot 10% volumeverlies is cosmetisch acceptabel
  - Tot 30% volumeverlies mogelijk met correctie

Achtergrond

- **Conflict tussen oncologisch doel (ruime excisie) en cosmetisch doel ("niet teveel")**

- **Toepassing directe reconstructie en reconstructieve technieken**

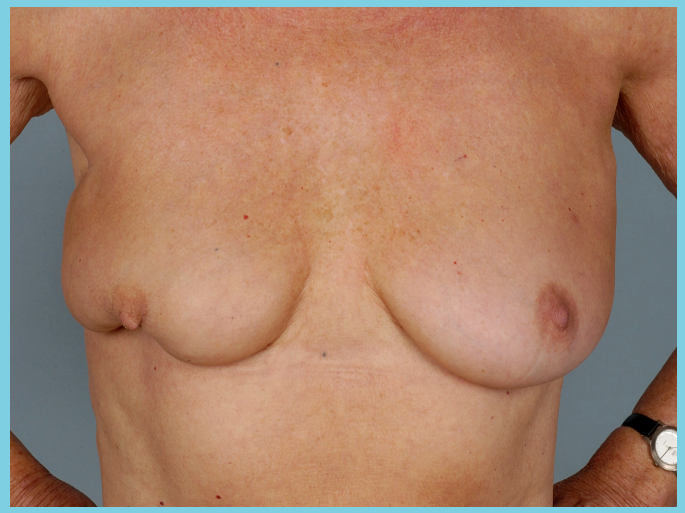

Erasmus MC

Waarom partiele borstreconstructie ?

- **Indicatie voor MST verbreden, als alternatief voor ablatio**
- **Minimaliseren van de kans op een slecht cosmetisch resultaat**

Table 1. Indications for Immediate Partial Mastectomy Reconstruction

Cosmetic Reasons	Oncological Reasons
High tumor to breast ratio (>20%)	Concern about clear margins
Tumor location—central, inferior, medial	Wide excision required
Macromastia	Poor candidate for mastectomy and reconstruction (i.e., age, breast size)
Large tumor	Patient desires breast conservation therapy
Patient desires smaller breasts	
Significant ptosis or breast asymmetry	

Classificatie van partial breast defects

Indeling naar grootte van het defect vs borstgrootte:

- Groot defect in grote borst → breast reshaping
- Medium defect in kleine borst → local flaps
- Groot defect in medium/kleine borst → distant flaps

Timing en snijranden

Table 3. Timing of Partial Breast Reconstruction*

Timing	Description
Immediate	At the time of resection
Delayed immediate	1–2 weeks after resection (confirmation of margins status)
Delayed	After radiation therapy

*The definitions are the same for both the volume displacement and volume replacement techniques.

Type reconstructie

- **Volume displacement**

  Verplaatsen en reshaping van het achterblijvende borstweefsel

- **Volume replacement**

  Reconstructie met lichaamseigenweefsel van donorplaats

Table 4. Partial Mastectomy Reconstruction Techniques

Volume Displacement Techniques	Volume Replacement Techniques
Parenchymal remodeling, volume shrinkage	Adjacent or distant tissue transfer, volume preserving
Primary closure	Implant augmentation (rare)
Mirror biopsy/excisions; batwing mastopexy	Local flaps (fasciocutaneous, perforator, and latissimus dorsi myocutaneous flaps)
Breast flap advancement techniques	Distant flaps
Nipple-areola centralization	
Reduction mastopexy techniques	

Classificatie van partial breast defects en behandelingsopties

Erasmus MC

Table 2. Classification of the Partial Mastectomy Defect with Potential Outcome and Treatment Options

Type	Description	Potential Outcome	Treatment
Type 1 (favorable)	Small, peripheral defect; large or small breasts	Breast shape is preserved with acceptable symmetry	Primary closure, BAF
Type 2 (unfavorable)	Medium to large defect; central defects	Size and shape deficiency with noticeable distortion and asymmetry	
Type 2a	Small breasts ± ptosis		Volume replacement procedures
Type 2b	Medium to large breasts ± ptosis	Quadrantectomy defect outside standard Wise pattern	Volume replacement technique
		Any lumpectomy defect	Volume displacement techniques
		Quadrantectomy defect within standard Wise pattern	
Type 3 (unfavorable)	Extensive resection with little remaining breast tissue; large or small breasts	Major deficiency	Mastectomy and reconstruction

BAF, breast advancement flap.

Wise patroon

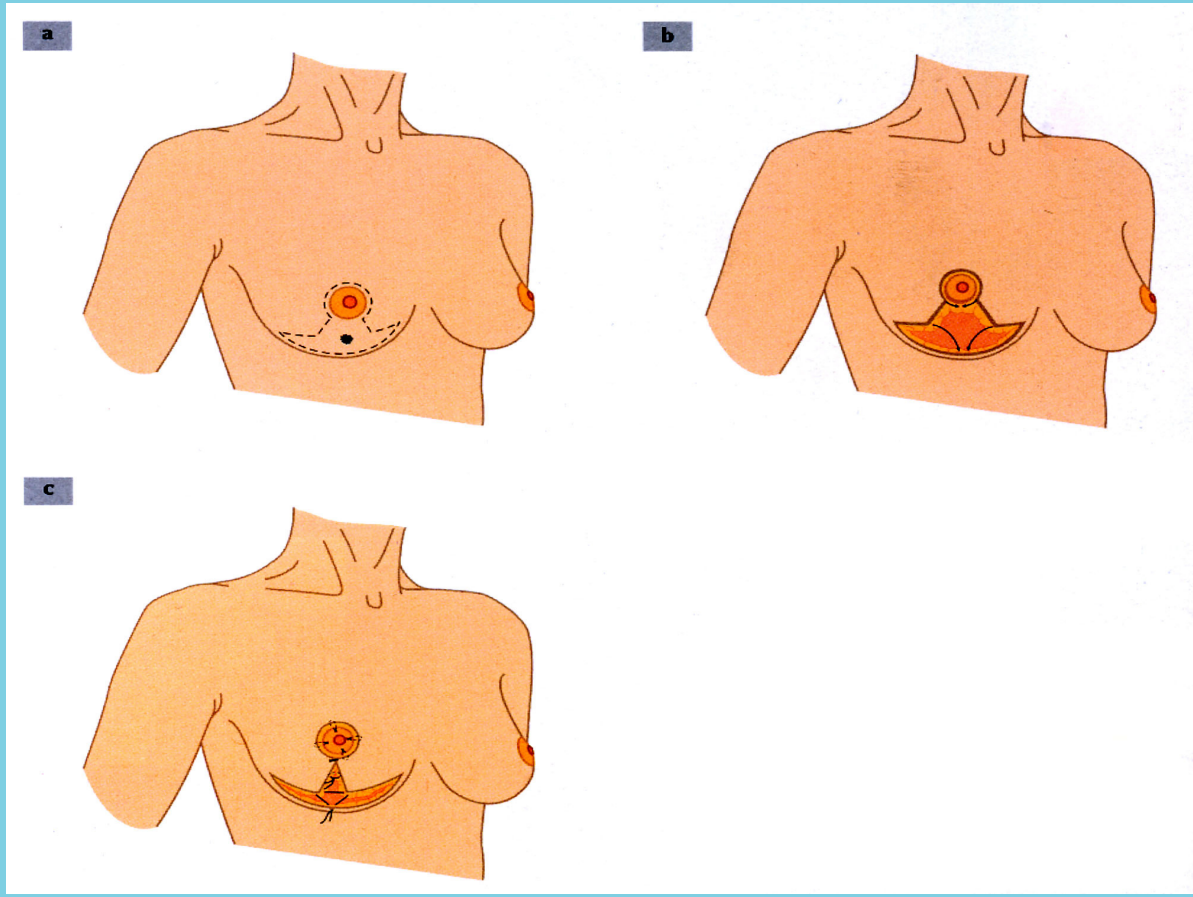

Volume displacement technieken

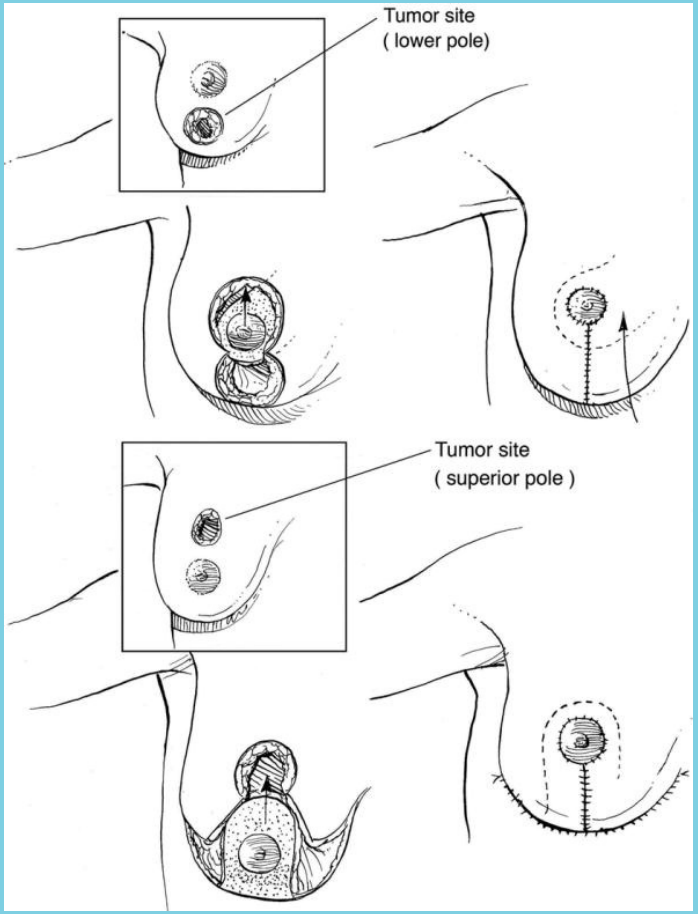

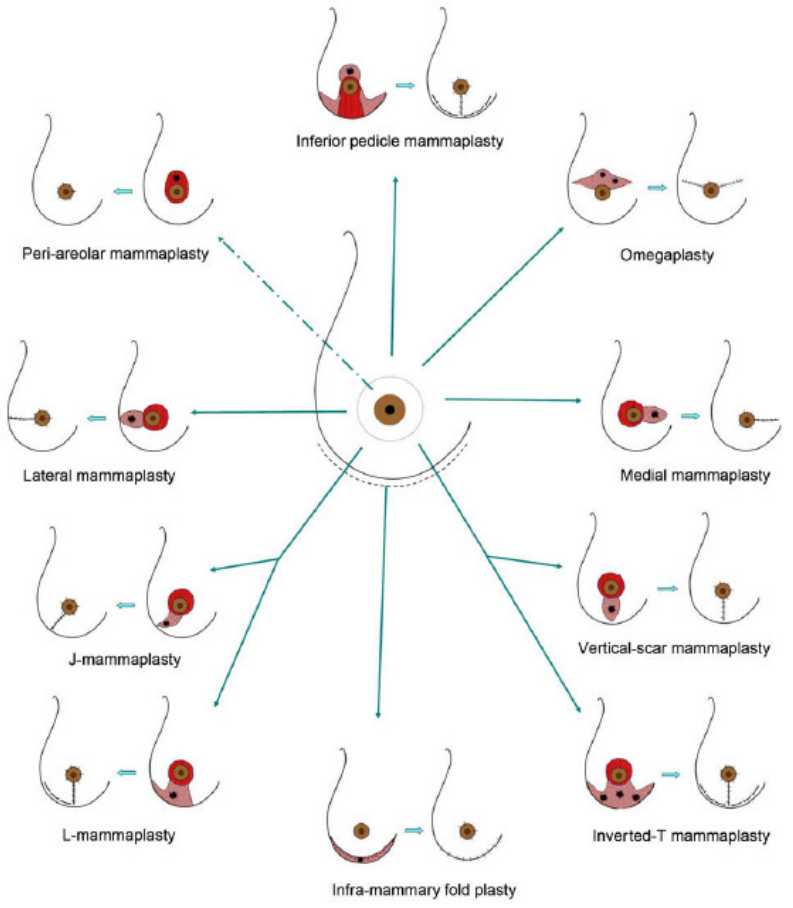

Volume displacement techniques

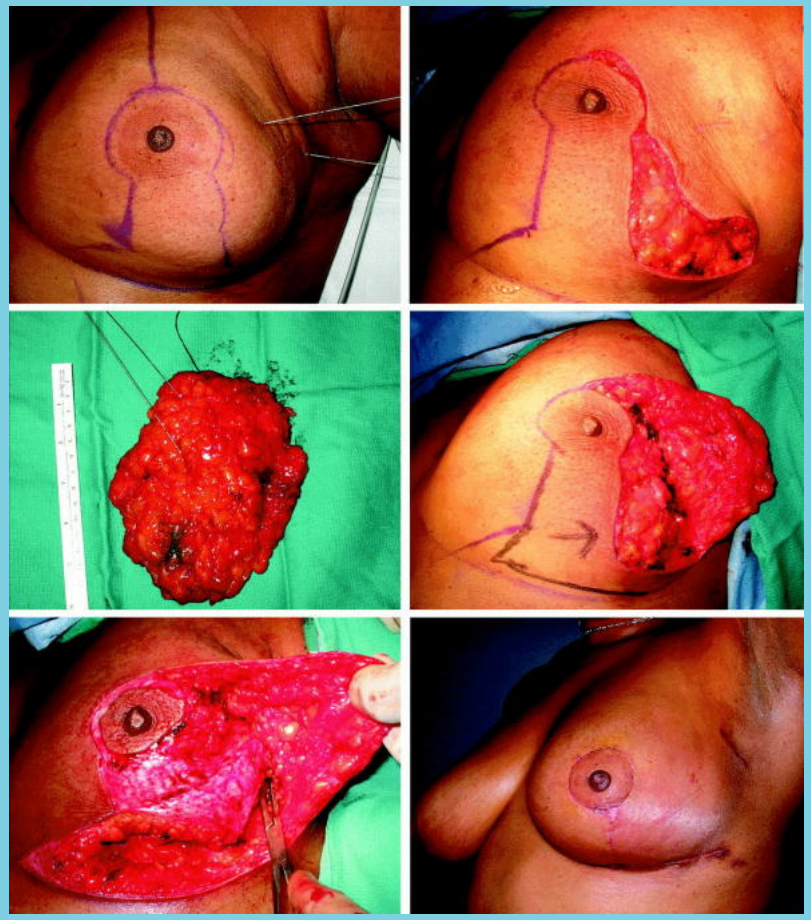

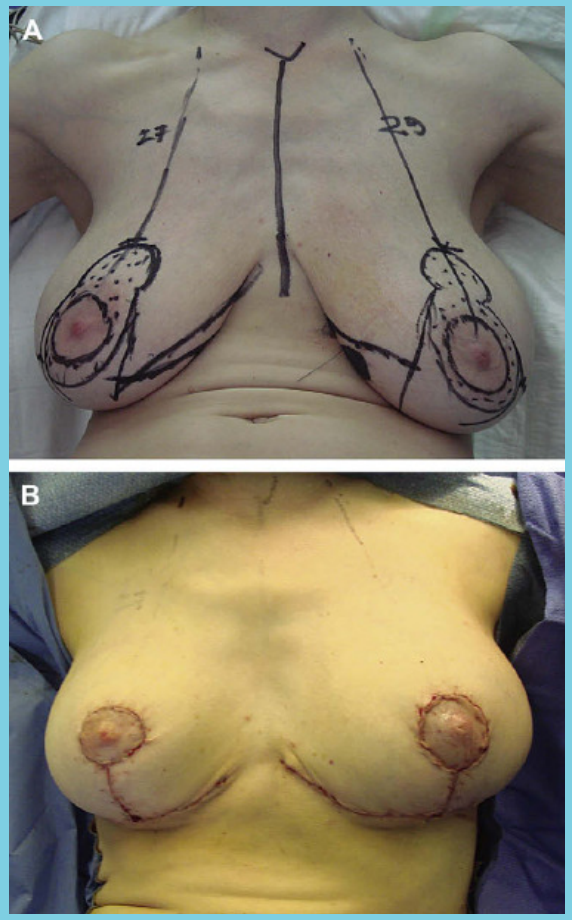

Volume displacement techniques

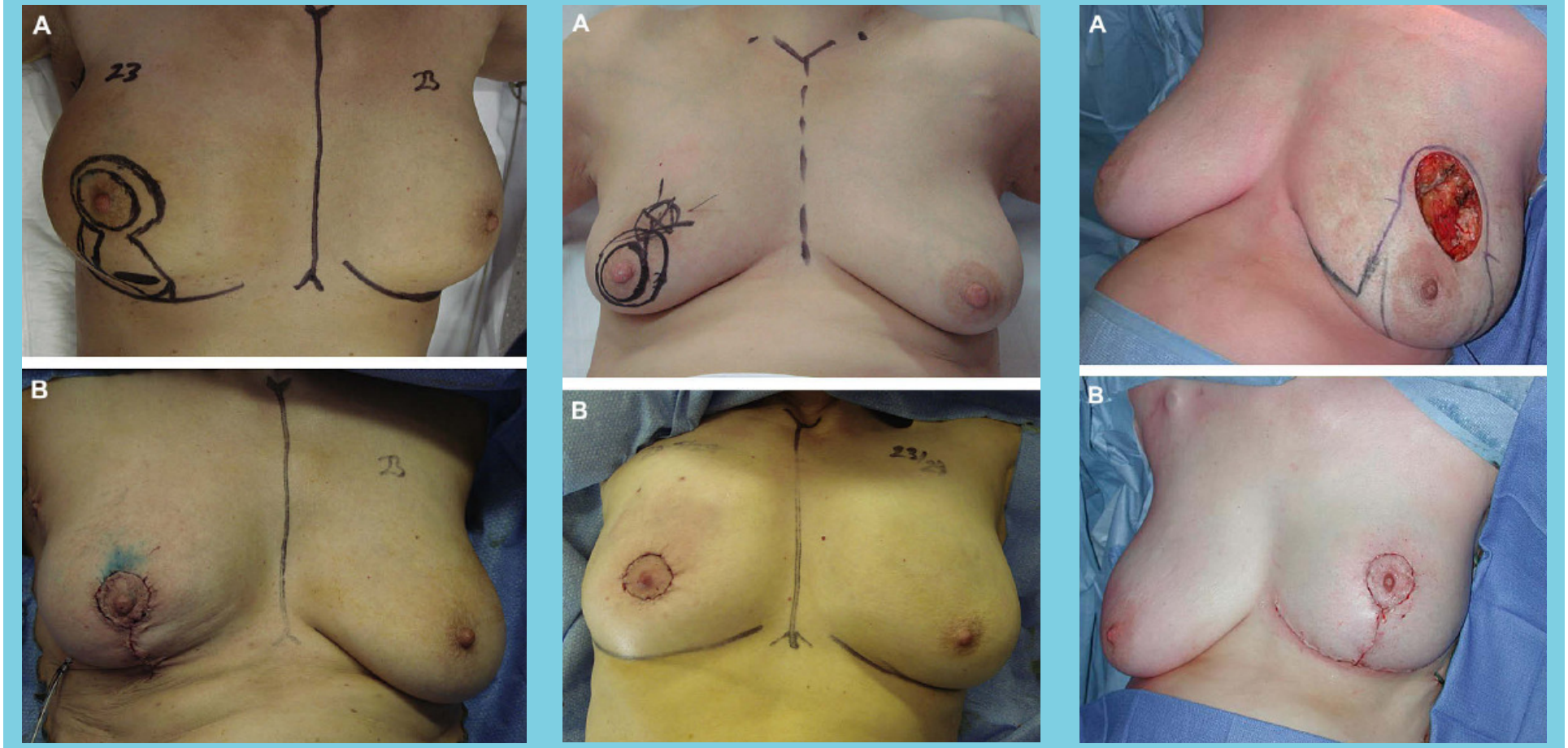

Volume displacement techniques

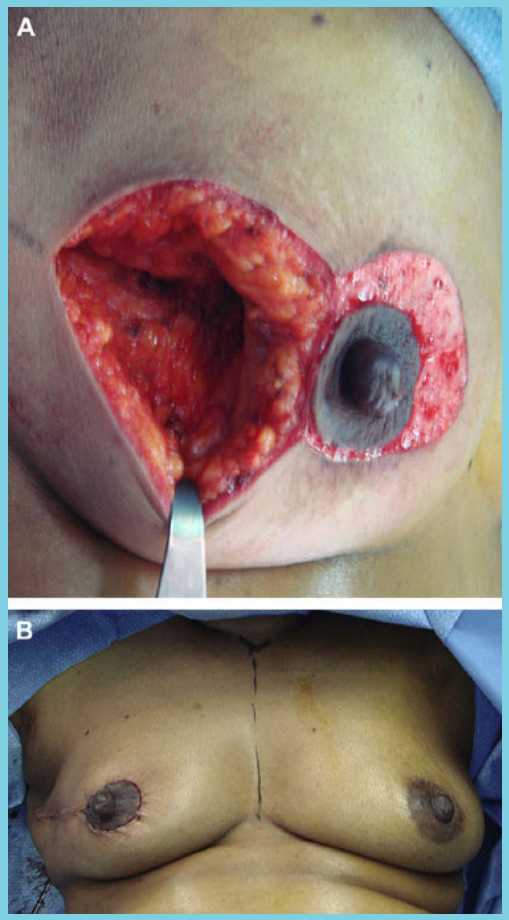

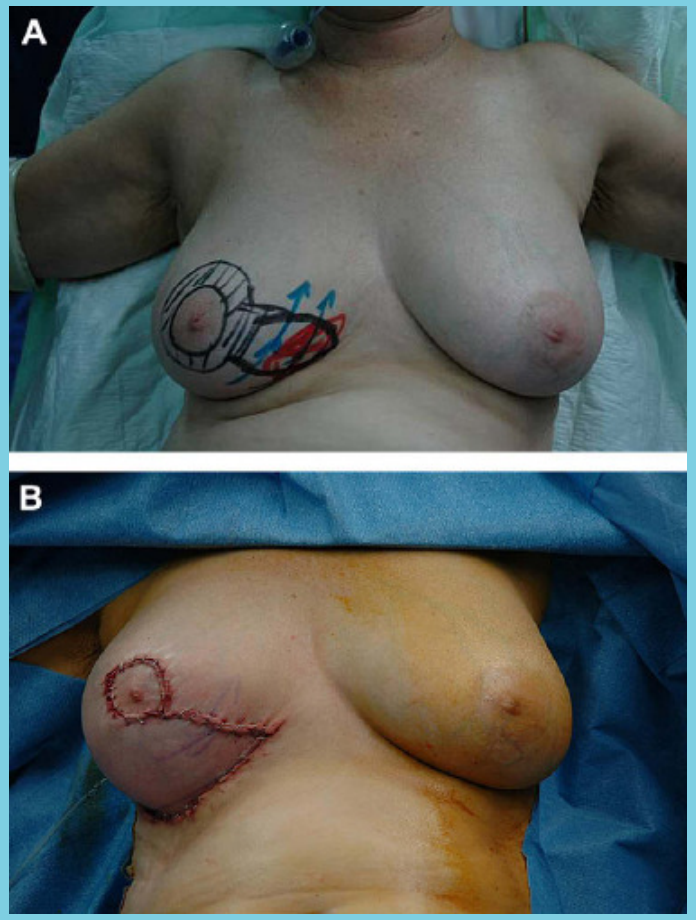

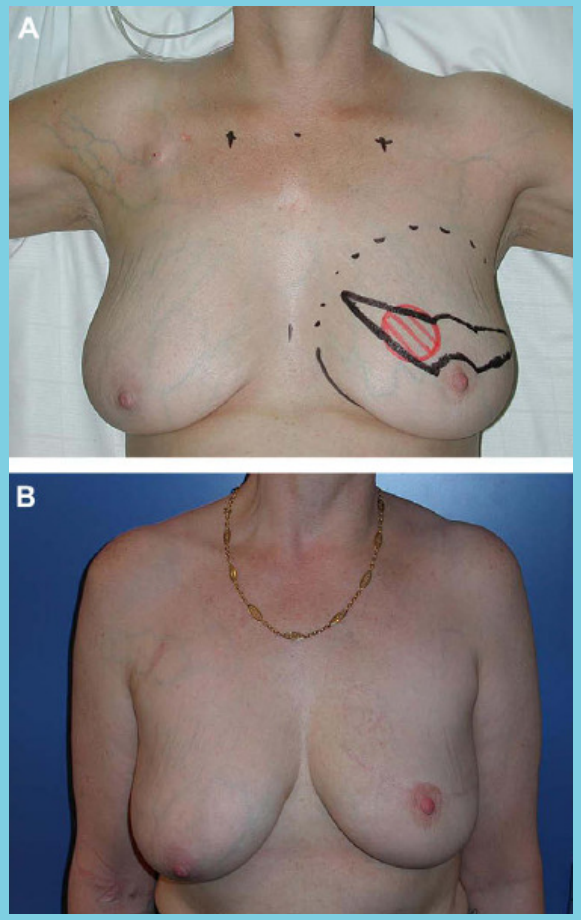

Volume replacement techniques

- Local fasciocutaneous flap
- Lateral thoracodorsal flap

Meest gebruikt:

- Latissimus dorsi flap
- Latissimus dorsi mini flap

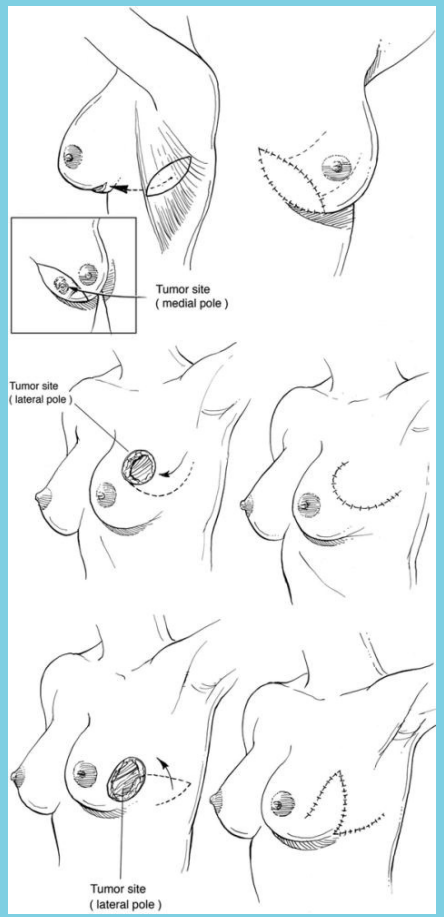

Volume replacement techniques – LD flap

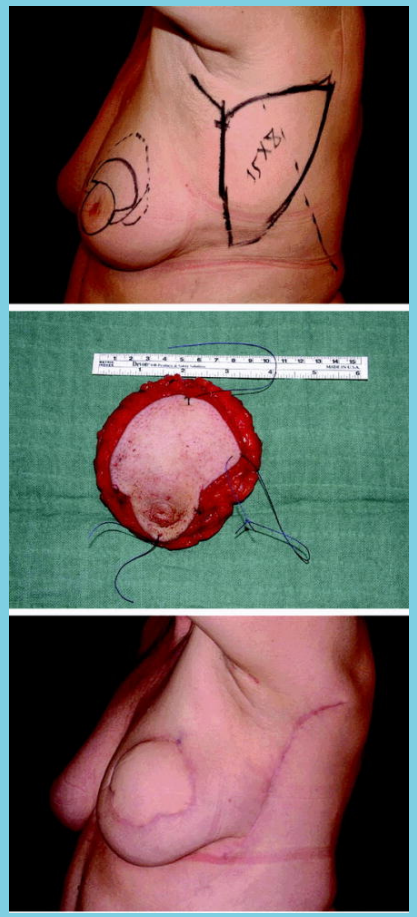

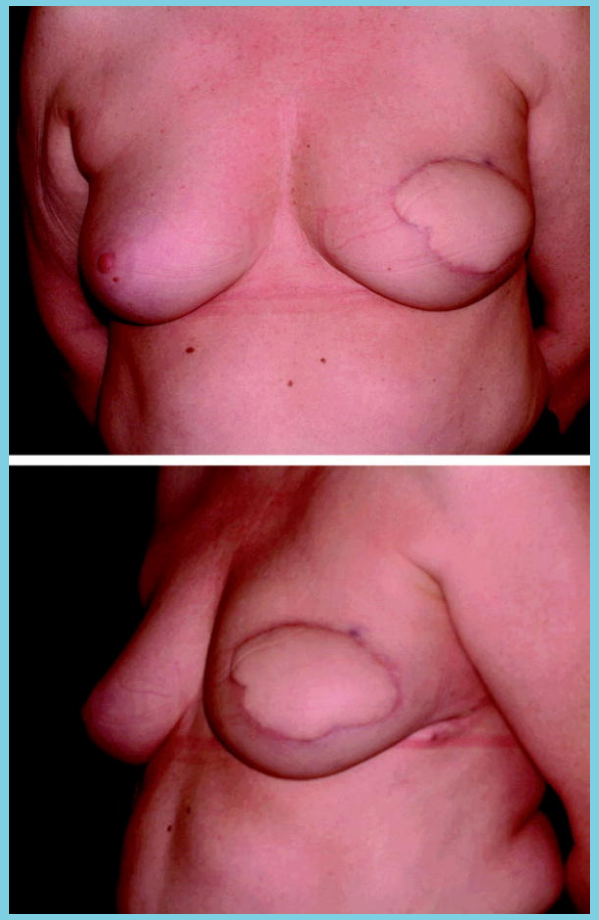

Delayed partial breast reconstruction

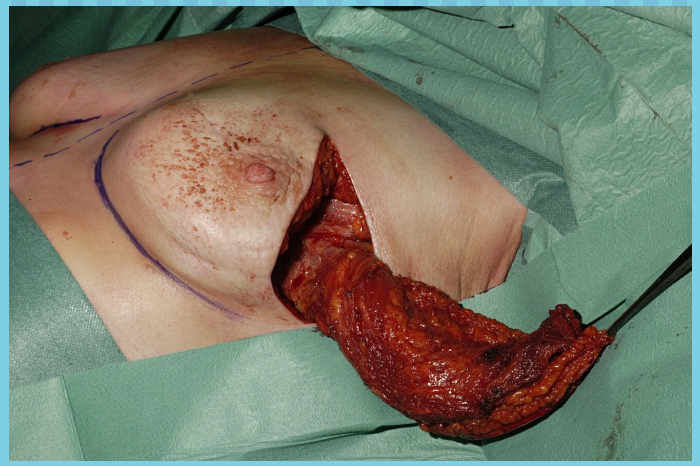

Oncologisch resultaat

- Ruimere resectie mogelijk (van 40-50 g tot > 230 g)
- Vermindering van positief snijvlak tot < 5%
- Contralaterale operatie → 2-5% synchrone tumor
- Local recurrence volgens norm MST

Table 5. Partial Mastectomy Reconstruction Using Reduction Techniques

Author	No. of Cases	Partial Mastectomy Specimen Weight (g)	Complications (%)	Cosmetic Result/Patient Satisfaction (Good to Excellent)	Local Recurrence (%)	Follow-Up (mo)
Losken et al.[16]	63	236	22	95	2	40
Clough et al.[41]	101	222	20	88	7	46
Munhoz et al.[48]	74		17	93	0	22
Goffman et al.[46]	55	NR	NR	72	13*	18
Chang et al.[47]	37	NR	19	70	0	

NR, not reported.
*High percentage of T3/T4 tumors.

Partial breast reconstruction algorithm

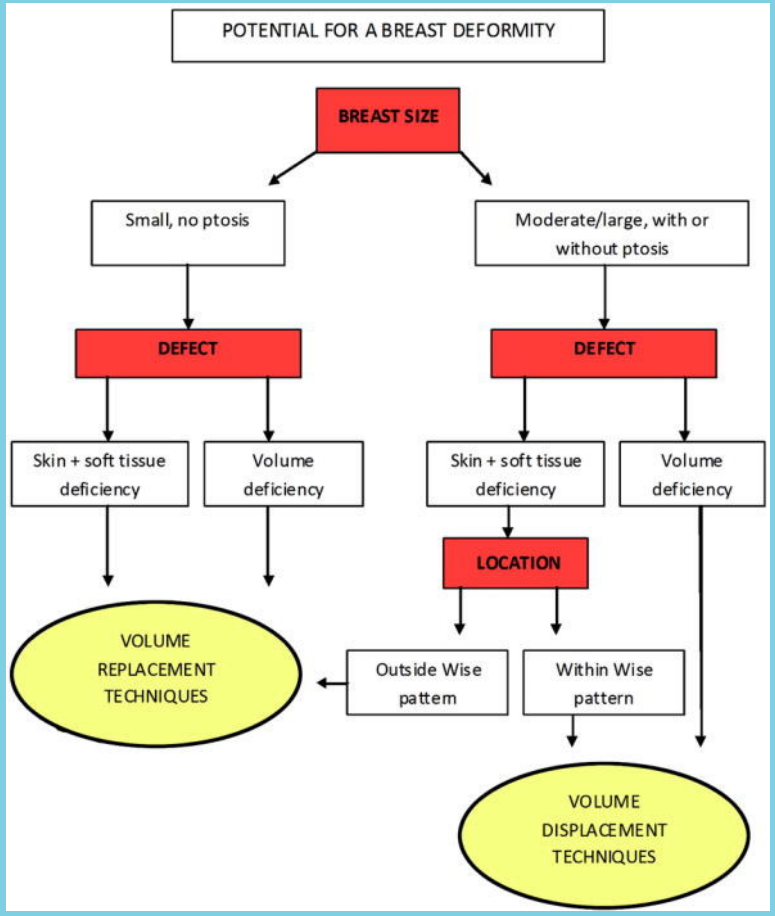

Richtlijn

- Richtlijn Mammareconstructie (NVPC), multidisciplinaire werkgroep vanaf november 2011.
  Hierin ook richtlijn oncoplastische chirurgie, partiele borstreconstructie en organisatie

- Oncoplastic Surgery – Aguide to good practice,
  EJSO 2007

Erasmus MC

References

- Losken A, Hamdi M. Partial breast reconstruction: current perspectives. Plast Reconstr Surg 124:722,2009

- Berry MG, Fitoussi AD, Curnier A, Couturaud B, Salmon RJ. Oncoplastic breast surgery: a review and systematic approach. J Plast Reconstr Aesthet Surg, 2009, doi:10.1016/j.bjps.2009.05.006
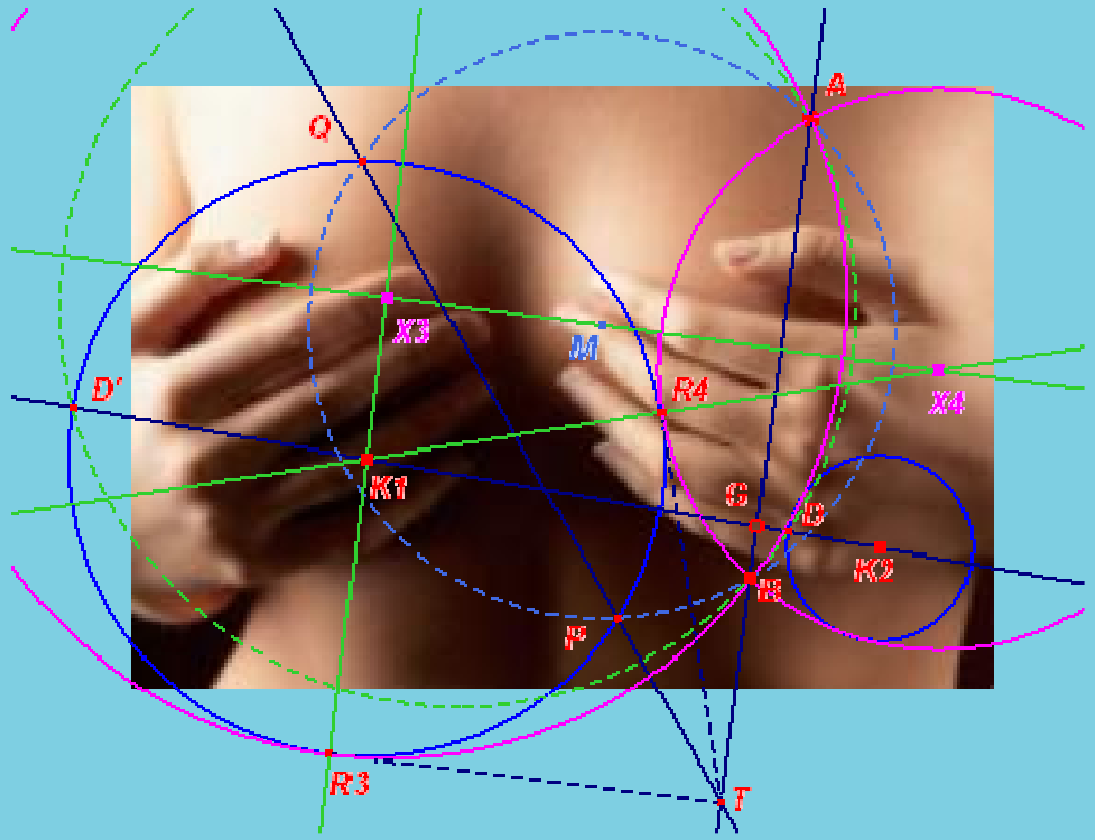
Dank voor uw aandacht !